

# Crowdsourcing the Ideal Nipple-Areolar Complex Position for Chest Masculinization Surgery

Wess A. Cohen, MD  
Rose S. Maisner, BS  
Nemesis Hazim, MD  
Haripriya S. Ayyala, MD  
Jonathan D. Keith, MD, FACS

**Background:** Chest masculinization surgery is increasing in prevalence. However, the ideal location of the nipple-areolar complex (NAC) is unknown. Our purpose was to determine the most aesthetically favorable male NAC position for use in chest masculinization through crowdsourcing.

**Methods:** Using Adobe Photoshop CC 2017, 8 locations for the NAC were created based on previous literature descriptions. Amazon Mechanical Turk was utilized as a crowdsourcing interface—respondents were asked to rank the top 3 most favorable and least favorable images. Analysis of variance with subsequent Tukey HSD was used for a statistical comparison of favorability scores for different NAC localizations. Values were considered significant with  $P < 0.05$ .

**Results:** Eight hundred nineteen respondents participated in the survey. NAC positions of Images C (mean score = 1.9222) and A (mean score = 1.7365) received higher favorability scores than those of Images D, E, F, G, and H (all  $P < 0.05$ ). There were no significant differences between Images C and A (C versus A:  $P = 0.6412$ ). NAC localizations from Images G (mean score =  $-2.0353$ ) and H (mean score =  $-1.6908$ ) received lower favorability scores than Images A, B, C, D, E, and F (all  $P < 0.05$ ). There were no significant differences between Images G and H ( $P = 0.2279$ ).

**Conclusions:** Most respondents preferred Images C and A, and few favored Images G and H, suggesting that lateral NAC placement is favored over more medial localizations. Additionally, both Images C and A utilize relatively inferior NAC placements. Therefore, we recommend a location inferior and lateral to the NAC. Ultimately, NAC localization during chest masculinization will be the result of shared decision-making between the patient and the surgeon to fulfill each patient's aesthetic goals. (*Plast Reconstr Surg Glob Open* 2020;8:e3070; doi: 10.1097/GOX.0000000000003070; Published online 18 August 2020.)

## INTRODUCTION

Gender dysphoria is defined as an incongruence between an individual's sex assigned at birth and the gender with which one identifies.<sup>1</sup> It is estimated that 0.39%–2.7% of the US adult population is gender non-conforming and that this percentage is increasing.<sup>2</sup> As a result of increased insurance coverage and evolving social norms, the number of gender-affirming surgeries being performed in the United States is exponentially rising.<sup>3</sup>

Chest masculinization is the most common and often first performed gender-affirming surgery.<sup>4,5</sup> This is because

breasts are a major female identifying characteristic and not easily concealed by clothes.<sup>6</sup> Transmale patients often resort to binding their breasts, which has been linked to multiple adverse effects on health, including musculoskeletal, neurologic, gastrointestinal, respiratory, and dermatologic sequelae.<sup>7,8</sup> A number of studies have demonstrated improved psychosocial quality of life after chest masculinization.<sup>9–11</sup>

Various surgical techniques for chest masculinization have been described. Depending on incision placement, the patient's excess tissue and nipple-areolar complex (NAC) is managed with more or less freedom and safety profile. Placement of the NAC is contentious in the literature, with some authors supporting the use of various landmarks such as the borders of the pectoralis muscle, midhumeral points, thorax circumference, and sternal length.<sup>12–17</sup> Yet, some authors prefer to rely on surgeon intuition.<sup>18,19</sup> Even though various other concepts of localizing the NAC have been published, management

From the Plastic & Reconstructive Division, Department of Surgery, Rutgers-New Jersey Medical School, Newark, NJ.

Received for publication April 7, 2020; accepted July 6, 2020.

Copyright © 2020 The Authors. Published by Wolters Kluwer Health, Inc. on behalf of The American Society of Plastic Surgeons. This is an open-access article distributed under the terms of the [Creative Commons Attribution-Non Commercial-No Derivatives License 4.0 \(CCBY-NC-ND\)](https://creativecommons.org/licenses/by-nc-nd/4.0/), where it is permissible to download and share the work provided it is properly cited. The work cannot be changed in any way or used commercially without permission from the journal.

DOI: 10.1097/GOX.0000000000003070

**Disclosure:** The authors have no financial interest to declare in relation to the content of this article.

continues to be perplexing to many surgeons. The authors aimed to determine the ideal location for the male NAC by using crowdsourcing technology.

## METHODS

To determine the most aesthetically favorable position for the NAC in chest masculinization, the authors crowdsourced opinions utilizing Amazon Mechanical Turk, a software providing access to a virtual community of survey takers. The survey collected each respondent's age; race/ethnicity; nation of origin; gender identity; sexual orientation; and the most favorite, second most favorite, third most favorite, and least favorite male chest images. Images were given favorability scores: 3 points if ranked first, 2 if second, 1 if third favorite, and -3 if chosen as the least favorite per respondent. Patients were paid 50 US cents for completion of the survey. Analysis of variance with subsequent Tukey honest significant difference (HSD) was used for a statistical comparison of favorability scores for different NAC localizations. Values were considered significant with  $P < 0.05$ .

To create a model for varied NAC placement, Adobe Photoshop Creative Cloud (CC) 2017 software was used to edit a digital image of a male torso found online. As the study analyzes transmale NAC placement, we used female parameters to adjust the image proportions. Under the assumption that the average height for women raised in the United States was 5'4" as per the Centers for Disease Control, the average torso length was calculated as the distance from C7 to the iliac crest. Because the average female torso is 14–18", we used the average, 16" or 40.64 cm, for creating our model.<sup>20</sup> To avoid nipple size interfering with nipple location, we utilized 2.5 cm for the NAC diameter, an average of NAC diameters encountered during our literature review.<sup>16,21–23</sup> For all images, we utilized the areolar width:height (W:H) ratio of 1.1 or 2.255:2.05 cm.<sup>16</sup>

Before generating the images, it was also important to establish the location of the fourth intercostal space (ICS). In studies done to determine appropriate electrocardiogram lead placement, the distance from the suprasternal notch (STN) to the right fourth ICS was found to be  $0.67 \times (\text{STN to xiphoid process length})$ .<sup>24</sup> In our model, this distance is 18 cm from the middle of the STN, placing the fourth ICS 12 cm caudal to the STN. The upper border of the NAC was placed here for models with parameters involving the fourth ICS for horizontal positioning.

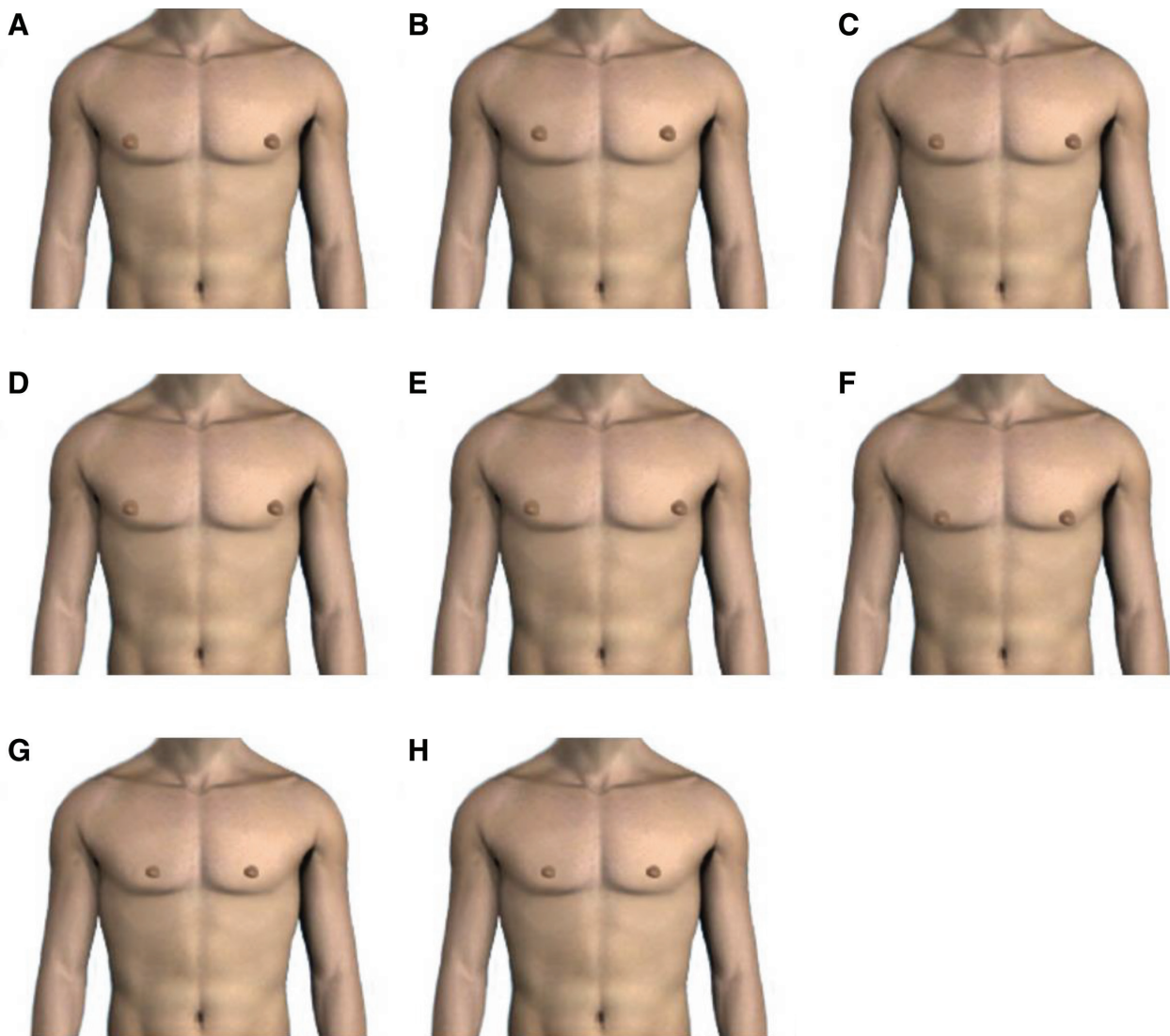
Previous research has proposed various measurements and formulas for idealization of the NAC location on the male chest. We utilized this research to model our images. Image A places the NAC 2.5 cm medial to the pectoralis muscle lateral border and 2.4 cm above inferior pectoralis insertion.<sup>16</sup> Image B utilizes a nipple-to-nipple (N-N) distance of 19.5 cm and suprasternal notch to horizontal nipple plane distance of 15.75 cm. This was calculated from the equations  $(\text{N-N}) = (0.618 \times \text{U-AX})$  and  $(\text{suprasternal notch to horizontal nipple plane}) = (\text{U-AX})/2$ , where U-AX is the umbilicus to axillary fold distance.<sup>25</sup> U-AX distance was determined to be 31.5 cm, using the measuring tool in the Adobe software and the assumed

average female height of 5'4". For Image C, the NACs are located 21 cm from each other.<sup>21</sup> Initially, we planned to also place the NAC 20 cm from the STN and 18 cm from the midclavicular line, but these did not fit the standard female torso.<sup>21</sup> To determine a top-to-bottom distance, we placed the NAC as close as possible to the pectoral border. Image D places the NAC at the fourth to fifth ICS about 11 cm from the sternal midline.<sup>22</sup> Image E utilized the fourth ICS and lateral border of the pectoralis muscle as landmarks for the ideal NAC placement, which is the preferred algorithm of the senior author (J.D.K.).<sup>17</sup> For Image F, we initially calculated the suprasternal notch (STN) to nipple distance as 16.9 cm, using the average ratio of the STN-to-nipple distance to the patient's height of 0.104 and assuming that the average female height is 162.56 cm.<sup>23</sup> However, this nipple plane fell off the chest, and we took the freedom to place the NAC as low as possible while still within the pectoral muscle borders. Using the average female chest circumference of 36" or 92 cm, N-N distance was calculated as  $0.190 \times \text{chest circumference} + 2.192$  to equal 19.67 cm.<sup>23</sup> Images G and H placed the NAC at 0.71 and 1.81 cm, respectively, from the mid-sternal line to accommodate more medial alignments as suggested by recent literature (Fig. 1).

## RESULTS

A total of 819 respondents participated in the survey. An estimated 65.39% were identified as men, 33.46% as women, and 0.38% as transgender. In total, 75.89% were categorized as heterosexual, 16.24% as bisexual, 2.54% as gay, 1.65% as lesbian, 1.02% identified as asexual, 0.76% identified as pansexual, 0.38% as queer, 0.76% as other, and 0.76% were unsure of their sexual orientation. Most participants were between 25 and 34 years old (51.97%), followed by 35 and 44 (19.06%) and 18 and 24 (16.90%) years old. Most respondents identified as White or Caucasian (55.85%), followed by Asian or Asian American (27.10%), Black or African American (6.87%), and Hispanic or Latino (5.60%). The respondents' most common countries of origin were the United States (64.2%) and India (20.3%) (Table 1).

NAC positions of Images C (mean score = 1.9222) and A (mean score = 1.7365) received higher favorability scores than those of Images D, E, F, G, and H (all  $P < 0.05$ , Fig. 2). Although Image B received a higher score than Images F, G, and H, its score was not significantly different from Images A, D, and E (B versus F, G, and H:  $P < 0.05$ ; B versus A, D, and E:  $P > 0.05$ , Fig. 2). In addition, Image B received a lower favorability score than Image C ( $P = 0.0220$ ). There were no significant differences between Images C and A (C versus A:  $P = 0.6412$ , Fig. 2). NAC localizations from Images G (mean score = -2.0353) and H (score = -1.6908) received lower favorability scores than Images A, B, C, D, E, and F (all  $P < 0.05$ , Fig. 2). There were no significant differences between Images G and H ( $P = 0.2279$ , Fig. 2).



**Fig. 1.** Models of NAC position. A, NAC is located 2.5 cm medial to the pectoralis muscle lateral border and 2.5 cm above the inferior pectoralis insertion. B, N-N distance is 19.5 cm, and STN-NN distance is 9.75 cm. C, N-N distance is 21 cm. NAC is placed as close as possible to the pectoral border. D, NAC is located at the fourth to fifth ICS about 11 cm from the sternal midline. E, NAC is located relative to the fourth ICS and lateral border of the pectoralis muscle. F, NAC is placed as low as possible within the pectoral muscle borders, and N-N distance is 19.67 cm. G, NAC is 0.71 cm from the midsternal line. H, NAC is 1.81 cm from the midsternal line.

## DISCUSSION

For individuals transitioning from being a woman to a man, breasts are constant reminders of biological sex rather than of true gender identity, which can negatively impact their mental well-being.<sup>6</sup> Although the prevalence of chest masculinization surgery is increasing, the ideal location of the NAC is poorly understood. Lindsay<sup>26</sup> and Berry et al<sup>27</sup> caution that the NAC is commonly misplaced “too high and too medial.” This malposition is caused by failure to account for the inferior and lateral location of the male nipple compared with the female nipple.<sup>26,27</sup>

In our survey, Image C had the highest mean favorability score, suggesting that it may display the ideal NAC localization. This model uses fixed measurements of 20 cm from the STN and 18 cm from the midclavicular line as well as for an N-N distance of 21 cm. Although this technique is

easy to reproduce, it fails to adjust for patient body habitus and proportions, especially in obese patients for whom using the midclavicular line as a landmark is subject to higher interobserver variation.<sup>21</sup> Additionally, as this technique was developed for gynecomastia, we ran into issues using these fixed parameters for female chest dimensions. Therefore, although Image C was most favored by survey respondents, measurements may not align for the average female chest and therefore some surgeon aesthetic judgment may be required. Plastic surgeons should be reassured, however, that their ideal nipple location closely resembles that of the general population.<sup>28,28</sup>

Image A had the second highest mean favorability score. This model was specifically designed for chest masculinization surgery and places the NAC 2.5 cm medial to the pectoralis muscle lateral border and 2.4 cm above inferior

**Table 1. Demographics of mTurk Survey Participants**

	No. Respondents (%)
Age	
Under 18	2 (0.25)
18–24	133 (16.90)
25–34	409 (51.97)
35–44	150 (19.06)
45–54	51 (6.48)
55–64	35 (4.45)
65+	7 (0.89)
Gender	
Male	514 (65.39)
Female	263 (33.46)
Transgender man	2 (0.25)
Transgender woman	1 (0.13)
Nonbinary	2 (0.25)
Agender	2 (0.25)
Unsure	0 (0.00)
Other	2 (0.25)
Sexual orientation	
Heterosexual	598 (75.89)
Gay	20 (2.54)
Lesbian	13 (1.65)
Asexual	8 (1.02)
Bisexual	128 (16.24)
Pansexual	6 (0.76)
Queer	3 (0.38)
Unsure	6 (0.76)
Other	6 (0.76)
Race	
White or Caucasian	439 (55.85)
Black or African American	54 (6.87)
Hispanic or Latino	44 (5.60)
Asian or Asian American	213 (27.10)
American Indian or Alaska Native	11 (1.40)
Native Hawaiian or other Pacific Islander	2 (0.25)
Other	23 (2.93)
Nation of origin	
United States	512 (64.16)
India	162 (20.30)
Brazil	13 (1.63)
Canada	8 (1.00)
United Kingdom	7 (0.88)
Australia	3 (0.38)
Other	33 (4.14)
Unspecified	60 (7.52)

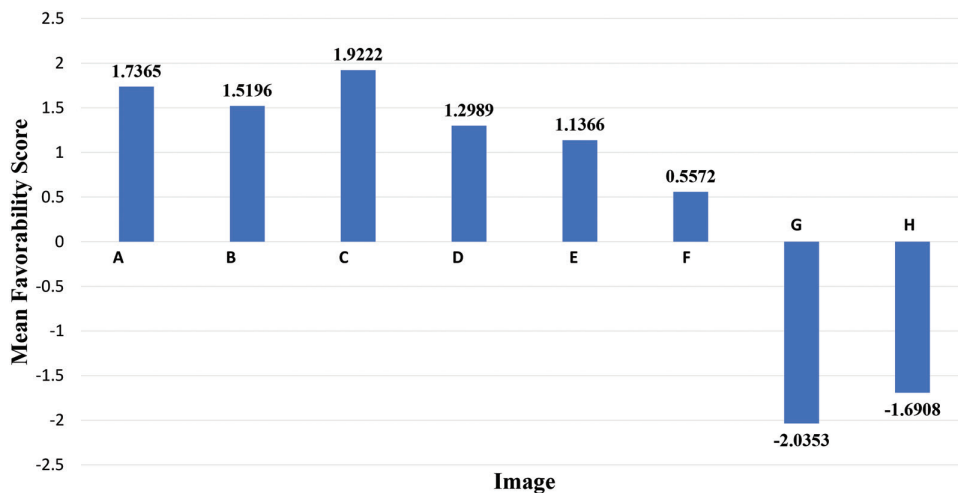
pectoralis insertion.<sup>16</sup> Although this technique is easy to reproduce and accounts for anatomical differences, it may be difficult to localize the pectoralis borders preoperatively in an obese patient, resulting in NAC placement that is too

superior or medial.<sup>16</sup> Both Images C and A place the NAC relatively lateral and low on the anterior male chest.

Images G and H had the lowest mean favorability scores, indicating that medial placement of the NAC is less aesthetically pleasing. Image B was ranked higher than Images F, G, and H, further supporting that the NAC should be placed more laterally in chest masculinization for an aesthetically pleasing result. Interestingly, Image B, which places the NAC more superior than in Image C, was scored lower than Image C. This result suggests that although the ideal male nipple should be placed relatively inferiorly, medial deviations are not tolerated and thus lateral positioning of the NAC is of the highest aesthetic priority. Also, the parameters of Image B may be less practical in an operating room setting, due to its use of mathematical formulas for NAC localization.<sup>25</sup>

**Limitations**

Although this study is the first to utilize crowdsourcing to determine the ideal NAC location in transmales, it does suffer from some limitations. Unfortunately with an online survey, we were unable to screen participants nor monitor participation; so we were unable to gauge how seriously the participants took the study. Furthermore, Amazon Mechanical Turk does not link demographic data to individual responses, and therefore, further analyses could not be accomplished. In addition, several respondents skipped one or multiple questions. Most of our survey respondents were cisgender men or women; so the results do not reflect the preferences of the patient population that these NAC positions would benefit. Additionally, the majority of our survey participants were from the United States or India. Also, our survey did not include images utilizing all chest masculinization-specific aesthetic parameters for NAC positioning in the literature. Future research should focus on eliciting the transgender population’s opinions specifically and the use of patient-reported outcomes measures for postoperative patients. Additionally, changes in body habitus may affect the ideal nipple location. Finally, although Agarwal et al.<sup>16</sup> suggest



**Fig. 2.** Preferred NAC positions of mTurk survey respondents ranking by favorability scores.

an areolar W:H ratio of 2.255:2.05 cm or 1.1, there is no consensus on how large the reconstructed nipple should be, which should be the focus of future studies for improving chest masculinization techniques.

## CONCLUSIONS

Most respondents preferred models of the male chest that included more inferior and laterally placed NACs. It also seems that more medial deviation of the NAC is more aesthetically egregious than superior deviations. Ultimately, final NAC placement and construction during chest masculinization will be based on shared decision-making between patient and surgeon to fit the patient's individual aesthetic goals.

**Jonathan D. Keith, MD, FACS**

East Coast Advanced Plastic Surgery  
200 S Orange Ave #295  
Livingston, NJ 07039  
E-mail: jonathankeith.md@gmail.com

## REFERENCES

- American Psychiatric Association; DSM-5 Task Force. *Diagnostic and Statistical Manual of Mental Disorders: DSM-5™*. 5th ed. Arlington, VA: American Psychiatric Publishing, Inc; 2013.
- Nolan IT, Kuhner CJ, Dy GW. Demographic and temporal trends in transgender identities and gender confirming surgery. *Transl Androl Urol*. 2019;8:184–190.
- American Society of Plastic Surgeons. Gender Confirmation Surgeries Rise 20% in First Ever Report. American Society of Plastic Surgeons website. Available at <https://www.plasticsurgery.org/news/press-releases/gender-confirmation-surgeries-rise-20-percent-in-first-ever-report>. May 22, 2017. Accessed October 17, 2019.
- Cohen WA, Shah NR, Iwanicki M, et al. Female-to-male transgender chest contouring: a systematic review of outcomes and knowledge gaps. *Ann Plast Surg*. 2019;83:589–593.
- The Report of The U.S. Transgender Survey 2015, National Center for Transgender Equality. Available at <http://www.ustranssurvey.org/report>. Accessed January 10, 2019.
- Dutton L, Koenig K, Fennie K. Gynecologic care of the female-to-male transgender man. *J Midwifery Womens Health*. 2008;53:331–337.
- Peitzmeier S, Gardner I, Weinand J, et al. Health impact of chest binding among transgender adults: a community-engaged, cross-sectional study. *Cult Health Sex*. 2017;19:64–75.
- Jarrett BA, Corbet AL, Gardner IH, et al. Chest binding and care seeking among transmasculine adults: a cross-sectional study. *Transgend Health*. 2018;3:170–178.
- Agarwal CA, Scheefer MF, Wright LN, et al. Quality of life improvement after chest wall masculinization in female-to-male transgender patients: a prospective study using the BREAST-Q and Body Uneasiness Test. *J Plast Reconstr Aesthet Surg*. 2018;71:651–657.
- van de Grift TC, Kreukels BP, Elfering L, et al. Body image in transmen: multidimensional measurement and the effects of mastectomy. *J Sex Med*. 2016;13:1778–1786.
- Poudrier G, Nolan IT, Cook TE, et al. Assessing quality of life and patient-reported satisfaction with masculinizing top surgery: a mixed-methods descriptive survey study. *Plast Reconstr Surg*. 2019;143:272–279.
- Wolter A, Diedrichson J, Scholz T, et al. Sexual reassignment surgery in female-to-male transsexuals: an algorithm for subcutaneous mastectomy. *J Plast Reconstr Aesthet Surg*. 2015;68:184–191.
- Lo Russo G, Tanini S, Innocenti M. Masculine chest-wall contouring in FtM transgender: a personal approach. *Aesthetic Plast Surg*. 2017;41:369–374.
- McEvenue G, Xu FZ, Cai R, et al. Female-to-male gender affirming top surgery: a single surgeon's 15-year retrospective review and treatment algorithm. *Aesthet Surg J*. 2017;38:49–57.
- Nelson L, Whallett EJ, McGregor JC. Transgender patient satisfaction following reduction mammoplasty. *J Plast Reconstr Aesthet Surg*. 2009;62:331–334.
- Agarwal CA, Wall VT, Mehta ST, et al. Creation of an aesthetic male nipple areolar complex in female-to-male transgender chest reconstruction. *Aesthetic Plast Surg*. 2017;41:1305–1310.
- Ayyala HS, Mukherjee T, Le T, et al. A three-step technique for optimal nipple position in transgender chest masculinization. *Aesthet Surg J*. 2020 [E-pub ahead of print].
- Monstrey S, Selvaggi G, Ceulemans P, et al. Chest-wall contouring surgery in female-to-male transsexuals: a new algorithm. *Plast Reconstr Surg*. 2008;121:849–859.
- Berry MG, Curtis R, Davies D. Female-to-male transgender chest reconstruction: a large consecutive, single-surgeon experience. *J Plast Reconstr Aesthet Surg*. 2012;65:711–719.
- REI. (2018). How to Size and Fit a Backpack | REI Expert Advice [online]. Available at <https://www.rei.com/learn/expert-advice/backpacks-adjusting-fit.html>. Accessed November 15, 2018.
- Beckenstein MS, Windle BH, Stroup RT Jr. Anatomical parameters for nipple position and areolar diameter in males. *Ann Plast Surg*. 1996;36:33–36.
- Frederick MJ, Berhanu AE, Bartlett R. Chest surgery in female to male transgender individuals. *Ann Plast Surg*. 2017;78:249–253.
- Shulman O, Badani E, Wolf Y, et al. Appropriate location of the nipple-areola complex in males. *Plast Reconstr Surg*. 2001;108:348–351.
- Day K, Oliva I, Krupinski E, et al. Identification of 4<sup>th</sup> intercostal space using sternal notch to xiphoid length for accurate electrocardiogram lead placement. *J Electrocardiol*. 2015;48:1058–1061.
- Atiyeh BS, Dibo SA, El Chafic AH. Vertical and horizontal coordinates of the nipple-areola complex position in males. *Ann Plast Surg*. 2009;63:499–502.
- Lindsay WR. Creation of a male chest in female transsexuals. *Ann Plast Surg*. 1979;3:39–46.
- Berry MG, Curtis R, Davies D. Female-to-male transgender chest reconstruction: a large consecutive, single-surgeon experience. *J Plast Reconstr Aesthet Surg*. 2012;65:711–719.
- Beer GM, Budi S, Seifert B, et al. Configuration and localization of the nipple-areola complex in men. *Plast Reconstr Surg*. 2001;108:1947–1952; discussion 1953.
- Kaotzani, C, Schneeberger SJ, Wormer B, et al. Current perceptions of the aesthetically ideal position and size of the male nipple-areolar complex. *ASJ*. 2020;40:NP228–NP237.